SmileFast: A Novel Approach to Efficient and Predictable Composite Smile Makeovers

Author:

Dr Thomas Sealey BChD, MMedEd, MSc Endo, is a multiple Award-winning cosmetic dentist and joint-owner of two private cosmetic dental practices where he lives in Essex, UK. Dr Sealey graduated from Leeds Dental University in 2006 and also holds an MSc in Endodontic Practice and a Masters degree in Medical Education. He is the co-inventor and co-owner of SmileFast™ and inventor of the Single-visit Orthodontic Lingual and Invisible Dual (SOLID) retention system. He has a special interest in achieving cosmetic smile makeovers using a minimally invasive approach and lectures on his techniques internationally. He has extensive experience in all aspects of cosmetic dentistry, utilising orthodontics, advanced esthetic composite restorations and ceramic smile design, to achieve perfectly natural smile transformations. Dr Sealey will be receiving the highly prestigious accomplishment of full accreditation to the British Academy of Cosmetic Dentistry in November, making him one of only 14 dentists in the UK to have achieved this.

Introduction:

Matrix techniques are commonly used to transfer the shape and form of a planned new smile from a digital or analogue wax-up model to a patient's teeth by using some form of stent and a suitable restorative medium, such as composite resin, to allow placement of a definitive restoration. There have been many variations on this technique, and all have inherent limitations and inadequacies. Often a flowable resin material is advocated for ease of placement and the idealised property of low-viscosity, but this comes at the sacrifice of mechanical strength and wear resistance. Many attempts have been made to improve the matrix transfer technique, but all have fallen short. In 2018 SmileFast ltd. launched a new concept in the UK and have since trained over one-quarter of all practicing UK dentists. This novel stent and application technique, which uses the preferred and superior paste resin composite, has now become commonplace and is the ideal solution for composite smile restorations using a matrix transfer. The following case presentation describes this technique in detail, with both the clinical sequence and the evidence-based rationale discussed.

Patient History:

The patient was a medically fit 24-year-old female and was deemed low caries risk with no concerning social habits. Her oral hygiene was good, and she was a regular dental attendee. She had excellent periodontal health and there were no concerning radiographic findings.

Diagnosis:

Her main concern was the size discrepancies and the spacing within her smile, specifically between the dominant central teeth and the microdontic lateral teeth. She was a class one occlusion with only minimal canine tip tooth surface loss, indicative of some tooth grinding, likely during the night. The alignment of her teeth was generally good, however the upper anterior 4 teeth had slight rotations and lacked symmetry. She had a low lip line and slightly deficient buccal corridors (Figure 1). Her aim was to achieve a brighter, whiter, and more balanced smile.

Figure 1. Frontal view – smile before

Treatment planning

After full consultation and discussing all the options, costs, timeframes, on-going maintenance and repair costs, the patient proceeded to explore her options. A full set of clinical photos and an intra-oral scan of her dentition was submitted to SmileFast where a digital mock-up for a restorative solution was returned (Figure 2). Using the SmileFast integrated 3D software allowed her to visualise and understand the proposed options with both a 6-unit and a 10-unit smile makeover set-up for discussion. It was explained that by taking the veneers onto the premolar teeth the smile could be broadened and the deficient buccal corridors filled. The longevity and esthetics of each type of anterior restoration was explained, with both ceramic and composite options discussed.

A putty trial stent was made on the 3D wax-up model of both the 6-unit and 10-unit mock-up and the proposed smiles were separately transferred over her teeth using a temporary crown and bridge bis-acryl material. This allowed the patient to visualise both of the different smile enhancement options and ensure she was happy and fully consented on the expected esthetic result; she decided to restore the anterior 6 teeth only. This visual try-in is essential to stimulate and engage in these conversations with patients to ensure complete understanding and robust consent is attained. In addition to ensuring the patient is fully agreed and consented to the planned clinical procedure, the trial appointment also allows the clinician to assess the teeth and smile for balance and function, better assessing how the restorations will affect the bite and guidance, which allows more diligent planning and opportunity for changes ahead of the final planned permanent restorations.

It was decided to enhance the patient's smile using 6 direct composite veneer restorations which would better balance the smile by improving the colour, size and proportions of the teeth. This was certainly a very minimally invasive treatment option for such a young patient and carried the most

minimal of biological risks to the teeth when compared to other, more invasive, treatment options such as ceramic veneers. All occlusal and potential parafunction influences were considered and as there were no contra-indicatory factors, it was deemed that a direct composite veneer approach would be the most favourable for this patient at this time.

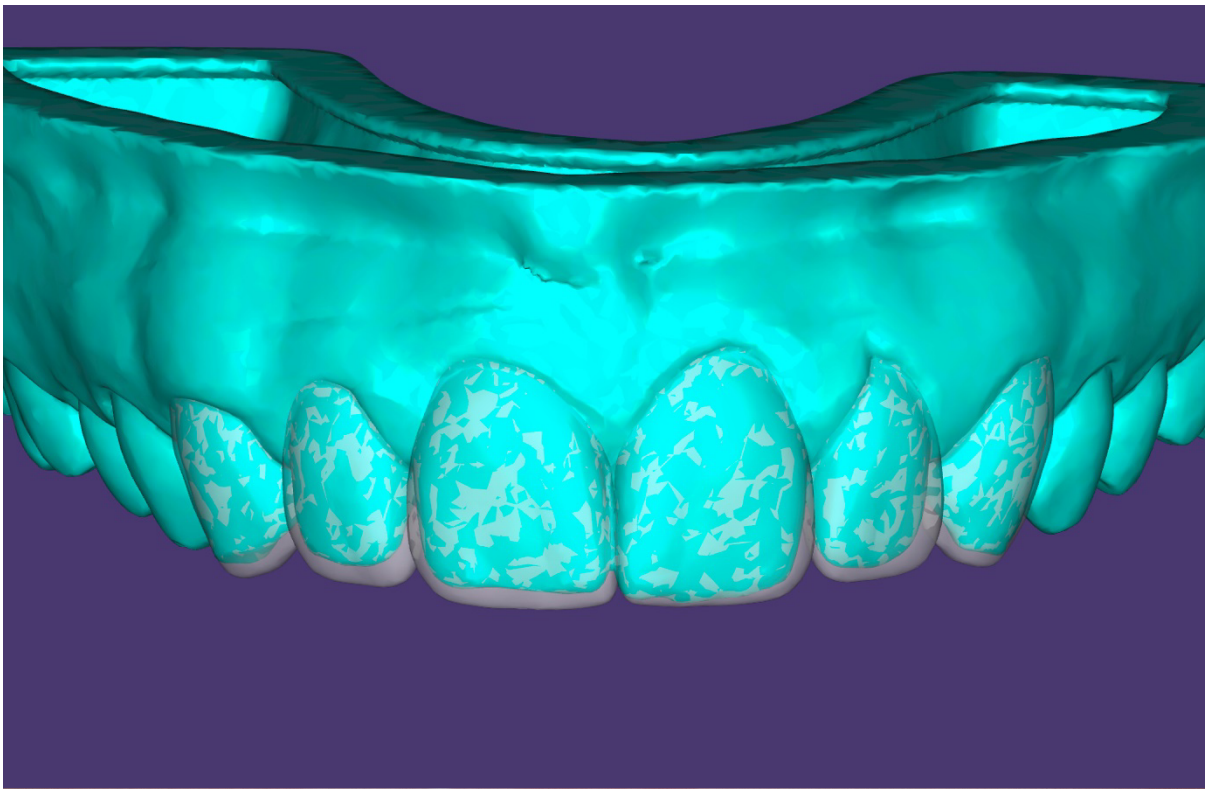

Figure 2. Screen shot from 3D digital smile planning

Treatment process

The patient began with a course of home tooth whitening using 10% carbamide peroxide whitening gel worn in trays overnight for three weeks. Once whitening was completed, any adhesive dentistry should be delayed by two weeks to allow the whitening process and oxidation effect to finish, and for full rehydration of the teeth to occur, before the patient returns for composite restorations.

Within this time the SmileFast stent was received with the chosen enamel shade of BLXL Empress Direct composite from Ivoclar (Figure 3). The key features of this stent, which improves upon all existing techniques, are that it has 0.038mm metal separators built within the stent itself. This means that when the stent is loaded with composite resin and is placed, the separators slide between the teeth and fully-separate them from each other. This prevents the composite from sticking together between the teeth and allows for up to 10 teeth to be fully restored in only one application. Additionally, the stent is made from an inner clear silicone transfer medium encased within a hard acrylic carrier; this allows for excellent dimensional stability and extremely accurate transfer of shape and texture from the digital wax-up to the natural teeth.

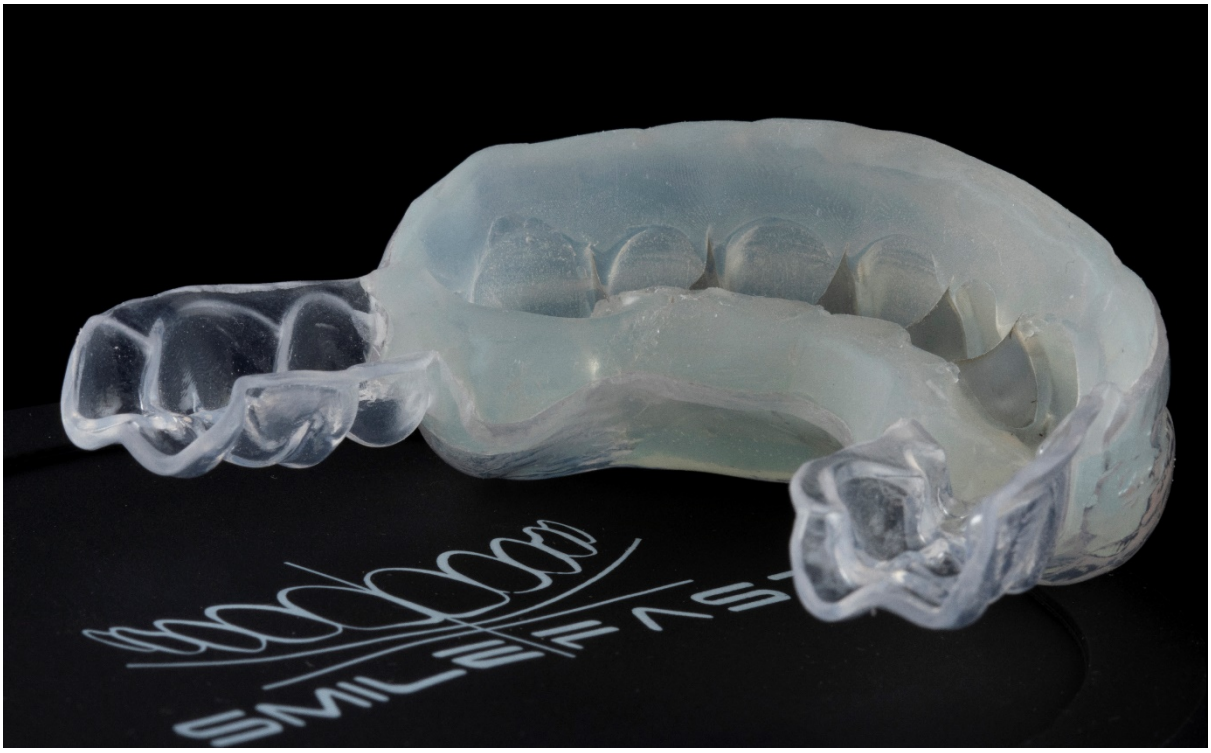

Figure 3. Older generation SmileFast stent

The SmileFast stent presented in this case presentation is of the older generation (Figure 3), with the new generation of stent shown in Figure 4. The enhancement over the previous design is the scalloping around the tooth margins and a thinner volume of silicone transfer medium, with a more rigid outer acrylic carrier. This scalloping allows access to the gingival contours of the teeth so much closer and more refined clean-up of any excess composite extruded at the gum margins can be completed before the composite resin is cured. The thinner inner silicone gives enhanced visualisation during seating and allows the light-cure unit to be closer to the teeth for enhanced light penetration during curing. Finally, the thicker outer carrier ensures absolute dimensional stability and complete confidence when restoring multiple teeth. The thicker carrier of the stent assists in resisting over-compression during placement, and therefore the shapes and sizes of the restorations remain precise, both facially, as well as accurately restoring vertical dimensions also.

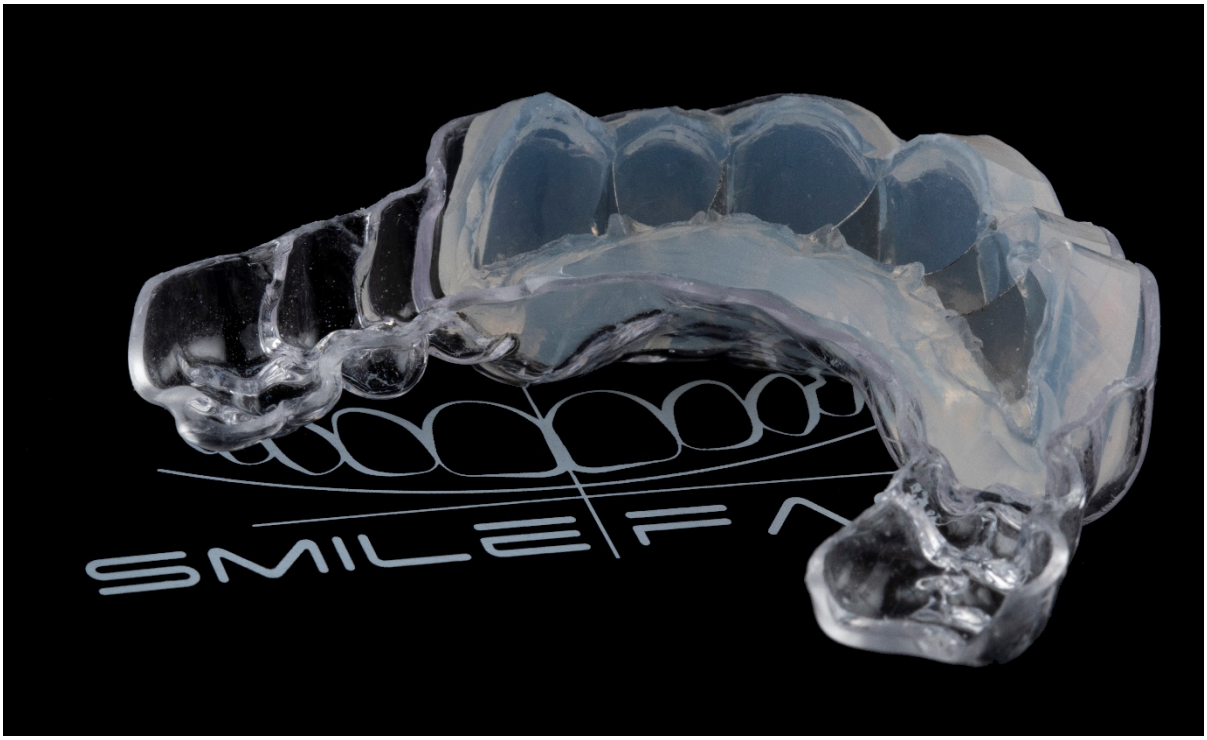

Figure 4. New generation SmileFast stent

On the day of placement (Figure 5), the stent was tried onto the patient's teeth to ensure accurate fitting before the teeth were isolated by placing a hydrophobic barrier of PTFE tape down into the sulci from tooth 6 to 11 (Figure 6). This acts as a barrier to both prevent gingival crevicular fluid contaminating the bonding zone, as well as preventing composite from traveling into the sulcus during the composite placement.

Figure 5. Pre-treatment teeth

Figure 6. Isolation

The neighbouring teeth were protected with a metal matrix strip and the teeth planned for restoration where microetched using an air abrasion unit with 50µ aluminium oxide powder to remove biofilm and increase micro-mechanical retention, followed by acid etching (Figure 7) and bonding protocol. A 3-step, 4th generation, adhesive bonding system was chosen as the entire surface to be treated on all teeth was within enamel. This technique places a separate acid etch on the enamel first before it is rinsed off. Then a priming stage is completed, and the primer allowed to evaporate, before the third stage of the adhesive bond placement (Figure 8). A total etch technique using a 4th generation system has been shown to offer the highest bond strengths to enamel when the technique is employed carefully and correctly. When there is exposed dentine, a selective etch technique utilising a 6th or 7th generation bonding system should ideally be used. This does not place a separate etch on the dentine first and utilises the short-acting and mild acidic component of the self-etching adhesive on the exposed dentine during the priming stage, which creates a thin hybrid-layer. This is less prone to hydrolysis than using a total-etch technique. Additionally, a more stable and durable bonding interface is created as there is only partial demineralisation of the dentine and consequent bonding to the hydroxyapatite crystal that remains [1,2].

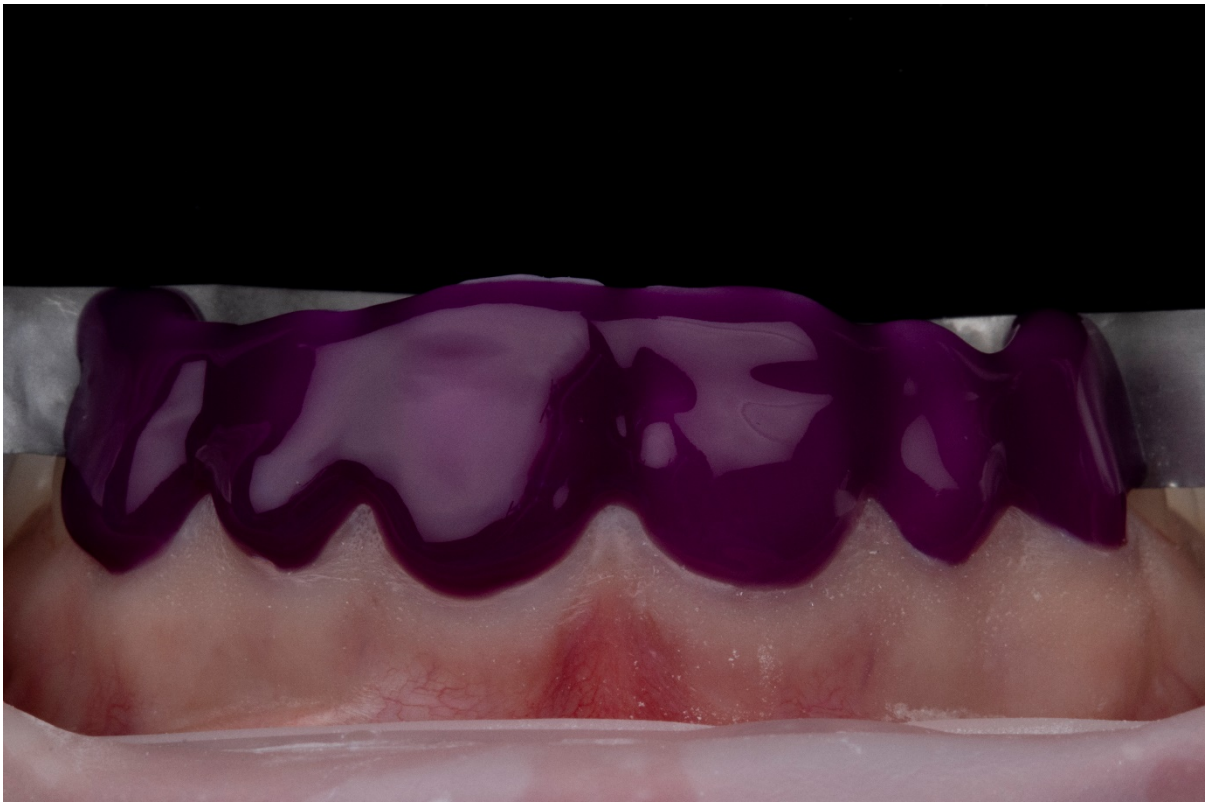

Figure 7. Acid etching

Figure 8. Bonding

Once tried in, the SmileFast stent was pre-loaded with heated paste composite and then placed on a heater to heat the entire stent to 140°F (Figure 9). Heating composite to this temperature is well-researched and shown to significantly improve the mechanical qualities of the material due to higher levels of monomer conversion when curing[3,4,5]. Better strength and wear resistance means that the

SmileFast restorations will be more durable, less prone to failure and maintain their lustre for far longer than using the inferior flowable composite resin techniques[6]. Heating the material decreases the viscosity which then allows it to flow under pressure when the stent is applied to the teeth. The excess material comes out of the palatal-incisal evacuation vents. With the new scalloped design stent (Figure 4) any excess composite that extrudes gingivally can now be easily cleared away before the restorations are cured through the stent, whereas in the old design cleaning around the teeth margins was impeded (Figure 10).

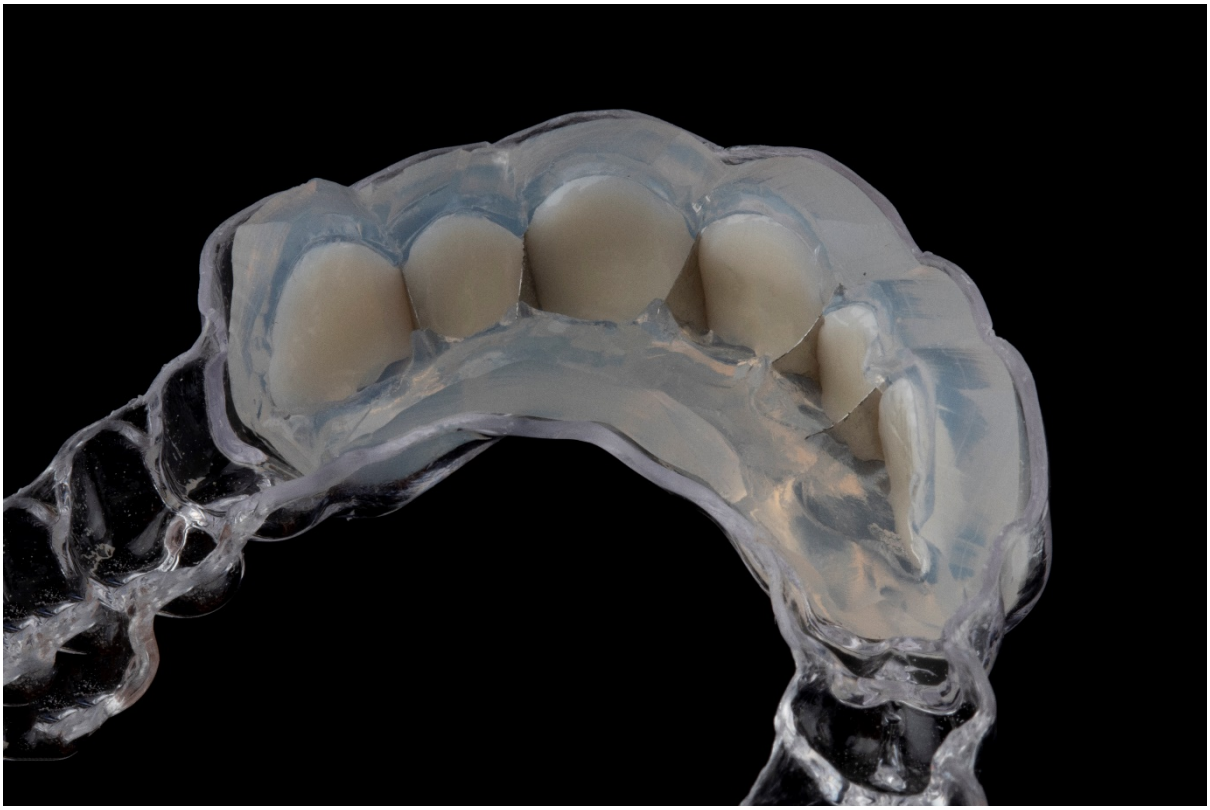

Figure 9. New generation stent preloaded with heated paste composite resin (example)

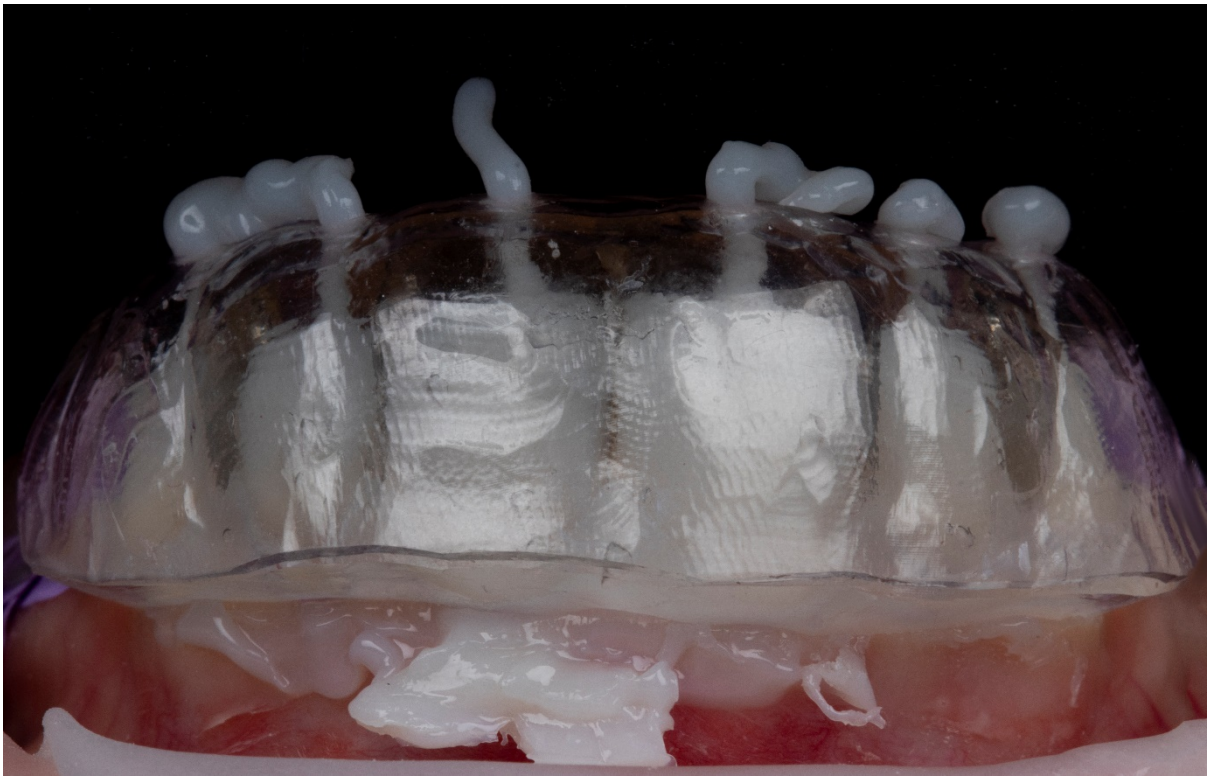

Figure 10. Stent placed

On removal of the stent the exact replication of the 3D virtual wax-up is perfectly transferred onto the teeth. The teeth are assessed for any voids or repairs, before a glycerine gel, or similar, is placed to seal the composite and they are given a final cure (Figure 11). Sealing composite is essential as the outer layer of resin is inhibited from fully curing due to the surrounding oxygen[6,7]. This leaves a sticky resinous layer on the outside of all freshly cured composite known as the Oxygen Inhibited Layer (OIL). If this OIL is not considered and removed before polishing begins, then one will find that composite will gather extrinsic stain very quickly and will lose its lustre also.

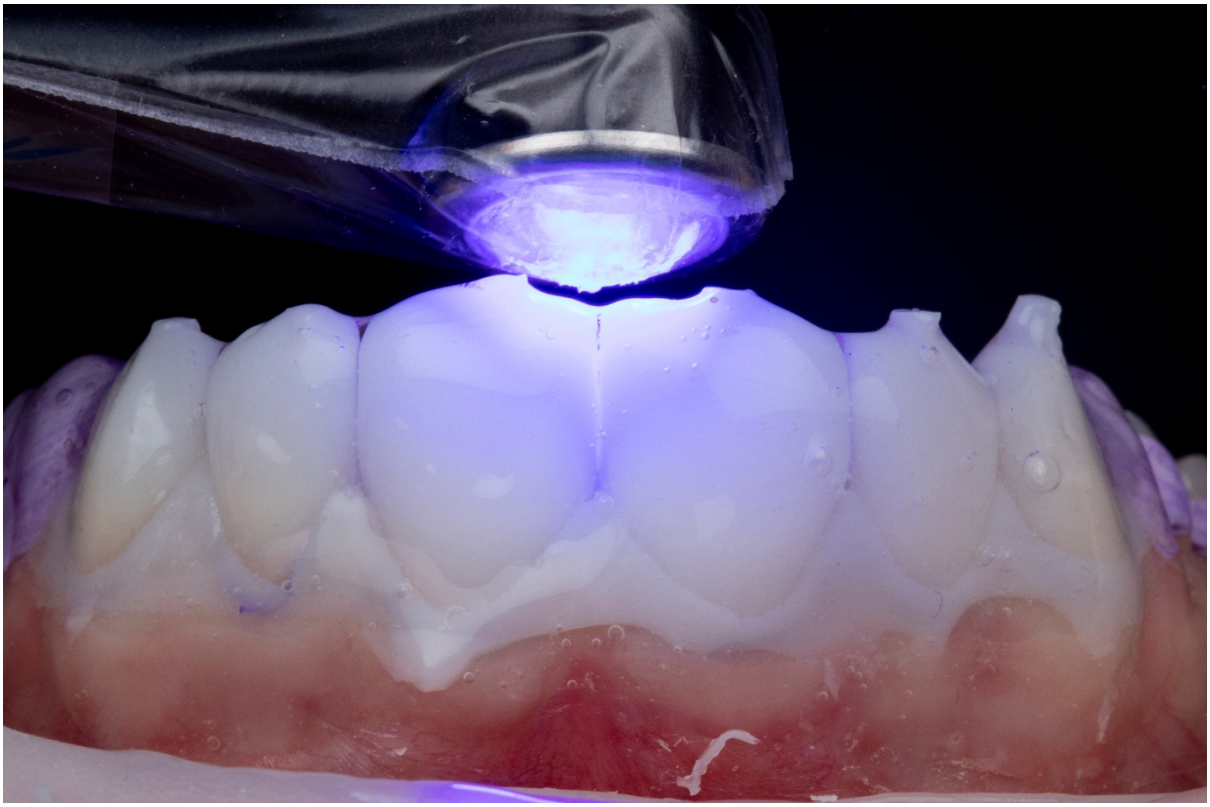

Figure 11. Curing the OIL

A careful sequence of marginal finishing burs were used to remove any excess composite and refine the margins to ensure a smooth transition from composite veneer to tooth (this is made significantly easier with the new generation stent as most of the excess material is removed before the light curing). Figure 12 shows the result after stent removal; where the primary marginal finishing is then completed before the excess composite material which extruded through the vents is removed from the incisal edges. The finishing sequence is then repeated, and interproximal strips used to smooth the cervical contours, before the final occlusal checks and any adjustments are made. Figure 13 shows the bleeding that occurs after removal of the PTFE. This is due to in influx of blood into the previously compressed capillaries and does not indicate gingival disease. After final margin refinement a simple two stage polish is completed using diamond-impregnated rubber wheels. In most circumstances, and with experience of the system, an 6-unit restoration case such as this one can be completed in 60 minutes (Figure 14).

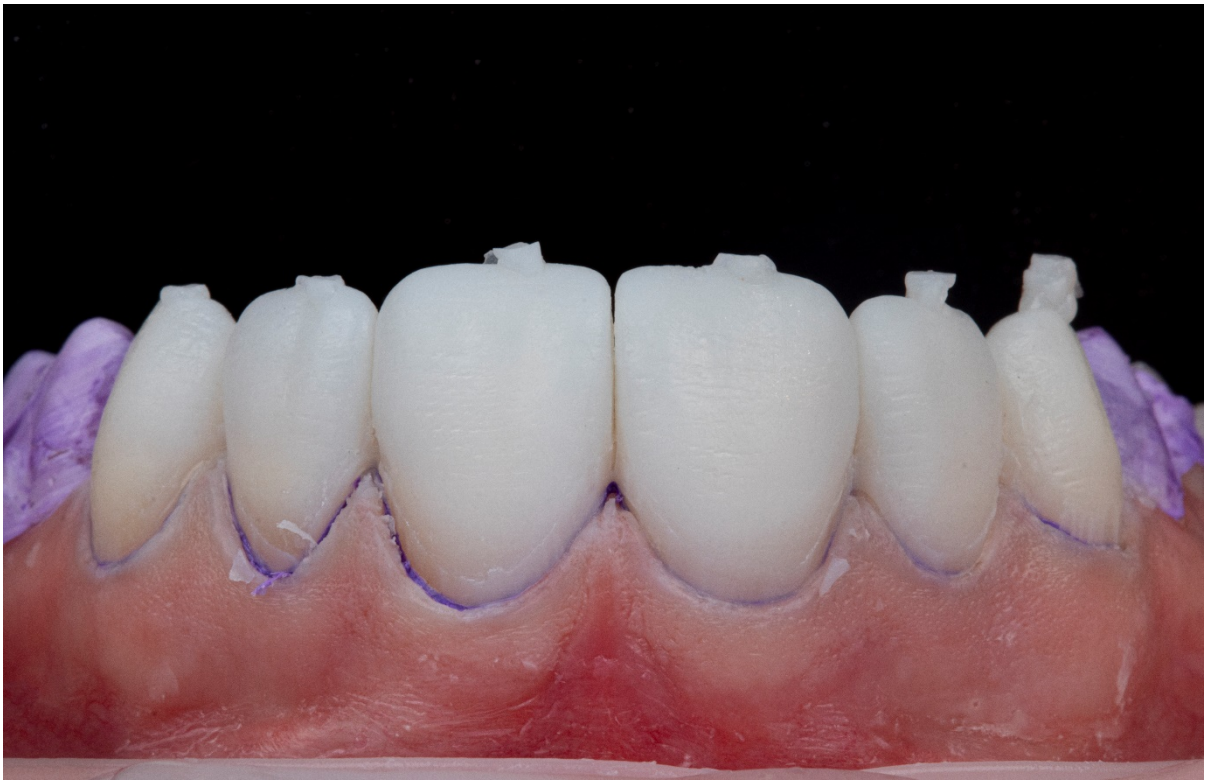

Figure 12. Immediate result after stent removal

Figure 13. PTFE removal

Figure 14. Immediate finished result

The patient returns after two weeks, and the composite restorations are given a second enhanced polish using cotton buffs and a 5µm polishing paste. All margins, occlusion and excursions are re-checked and any adjustments made (Figure 15 & 16). Note the beautiful tooth morphology and the detailed surface texture that is all provided through the SmileFast stent, no shaping or additional texturizing is necessary by the treating clinician. Any evidence of occlusal disease or parafunctional habits are addressed and managed with occlusal splint therapy prior to placing the composite restorations. For patients with no signs of previous occlusal disease a minimum of an Essix retainer is provided.

Figure 15. Final result 2 weeks post-treatment – frontal view

Figure 16. Final result 2 weeks post-treatment – oblique lateral view

Reflection

Achieving perfect and natural smile esthetics with composite has always been an incredibly time-consuming and high-skill procedure; however, now with the SmileFast system offering mentor-assisted case selection, patient participation in the design and consent process, and the guided delivery of the restorations using the unique SmileFast stent, dentists can now feel very confident in offering this type of treatment modality to their patients. Providing patients a planning pathway that shows them all of the options and allows them to explore different routes to achieve a better smile is incredibly important, not only to build trust, but also to ensure better consent so that what they ultimately decide on is based upon a more informed and considered understanding of the techniques, risks and expected results.

By approaching multiple veneer restorations in the same methodical and planned approach every time, the SmileFast protocol guarantees predictable and consistently excellent esthetic results. Figure 17 shows the composite veneer makeover as a direct comparison of the final-result to the planned digital design; the accuracy of transfer is very precise, with the natural texture and the detailed morphology being replicated exactly. For restorations such as these to last well and maintain their lustre, the choice of composite material is a critical component as it is essential to have the very best mechanical and esthetic properties. A nano-hybrid or micro-hybrid paste composite resin is ideal when delivering these smile makeovers that need to be both beautiful, and long-lasting[9]. This is where the SmileFast technique revolutionises what has come before, by allowing delivery of up to 10 restorations all at the same time using a direct resin approach and by using the superior properties of a paste composite.

Figure 17. Result comparison to digital plan

This patient's smile is now better balanced, with whiter teeth and more symmetry to the shapes (Figure 18). She was involved in every step of the planning and was able to trial the smile, as both a 6-unt and a 10-unit makeover, before she decided to proceed. This step is essential to ensure that the patient expectations have been met, and also to assess the function of the teeth within the smile to test that your planned restorations will not cause interferences or speech changes etc. The final composite smile will require twice yearly polishing to maintain lustre and the literature supports an expected longevity of 5-7 years, with only minimal repair, if necessary, within that timeframe[10,11,12]. For a patient of only 24 years-old, this is a carefully considered and modern approach to smile improvements that minimise biologic risk to the teeth but ensure predictability and superior function and esthetics.

Figure 18. Frontal view – smile after

References:

1. Van Meerbeek B, Yoshihara K, Yoshida Y, Mine A, De Munck J, Van Landuyt KL (2011) State of the art of self-etch adhesives. *Dental Materials*; **27**(1): 17-28.
2. Van Landuyt KL, Yoshida Y, Hirata I, Snauwaert J, De Munck J, Okazaki M *et al*. (2008) Influence of the chemical structure of functional monomers on their adhesive performance. *Journal of Restorative Dentistry*; **87**(8): 757-61.
3. Daronch M, Rueggeberg F, Fernando de Goes F (2005) Monomer Conversion of Pre-heated Composite. *Journal of Dental Research* 84(7):663-667.
4. Wagner WC et al. (2008) Effect of pre-heating resin composite on restoration microleakage. *Operative Dentistry*;33(1):72-8
5. Calheiros FC, et al. (2014) Effect of temperature on composite polymerization stress and degree of conversion. *Dental Materials* 30(6):613-8.

6. Vajani D, Tejani T H, Milosevic A (2020) Direct Composite Resin for the Management of Tooth Wear: A Systematic Review. *Clinical Cosmetic Investigational Dentistry*; 12: 465–475.
7. Ruyter IE (1981). Unpolymerized surface layers on sealants. *Acta Odontologica Scandinavica* 39(1):27-32.
8. Finger WJ, Lee KS, Podszun W (1996). Monomers with low oxygen inhibition as enamel/dentin adhesives. *Dental Materials* 12(4):256-61.
9. Baroudi K, Rodrigues JC (2015) Flowable Resin Composites: A Systematic Review and Clinical Considerations. *Journal of Clinical and Diagnostic research* 9(6): 18–24.
10. Peumans M, et al. (1997) The 5-year clinical performance of direct composite additions to correct tooth form and position. *Clinical Oral Investigations*; 1(1):12–18.
11. Wolff D, et al. (2010) Recontouring teeth and closing diastemas with direct composite buildups: a clinical evaluation of survival and quality parameters. *Journal of Dentistry*; 38(12):1001–1009.
12. Gresnigt MM, Kalk W, Özcan M (2012) Randomized controlled split-mouth clinical trial of direct laminate veneers with two micro-hybrid resin composites. *Journal of Dentistry*; 40(9):766–775.